

ULTRASOUND IN DIAGNOSIS OF HEPATIC PATHOLOGIES

A review of two years experience in University of Nigeria Teaching Hospital,
Enugu, Nigeria

Okoye I.J; Eke C.I; Aderibigbe A.S.O; Okere P.C.N; Ezeofor S.N.; Obioha F.I.
Department of Radiation Medicine,
University of Nigeria Teaching Hospital, Enugu, Nigeria

ABSTRACT

We have tried to evaluate the diagnostic yield of abdominal sonology for detection of liver pathologies by reviewing the ultrasonic findings in our department over a period of two years. Analysis of 879 patients that underwent abdominal sonography between 2001 and 2002 revealed relative incidences of liver, renal, splenic, pancreatic and cholecystic pathologies. 43 cases out of those clinically suspected to have pathology related to liver, were ultrasonically negative.

Evaluation of the 289 patients with positive ultrasound findings for liver pathology revealed that 46% of them were clinically suspected to have liver related pathologies while 54% were not clinically suspected. Specific types of liver disorders investigated over this period were hepatomegaly, cirrhosis, fatty degeneration, hepatoma, metastatic deposits and liver abscess. Of these the most commonly associated finding with detectable liver pathology was ascities. Our analysis suggests the liver sonology is useful for confirming clinically suspected cases of liver pathology and for revealing false positive and false negative liver cases.

ABSTRAIT

Nous avons essayé d'évaluer le rendement diagnostique de sonology abdominal pour la détection des pathologies de foie en passant en revue les résultats ultrasoniques dans notre département pendant deux ans. Analyse de 879 patients qui ont subi le

sonography abdominal entre 2001 et 2002 ont indiqué des incidences relatives de foie, rénal, splénique, pathologies pancréatiques et cholecystic. 43 cas hors de ceux médicalement suspectés pour avoir la pathologie liée au foie, étaient par ultrasons le négatif.

L'évaluation des 289 patients présentant des résultats positifs d'ultrasons pour la pathologie de foie a indiqué que 46% d'entre eux ont été médicalement suspectés pour avoir des pathologies reliées par foie alors que 54% n'étaient pas médicalement suspectés. Les types spécifiques de désordres de foie étudiés au-dessus de cette période étaient hépatomégalie, cirrhose, dégénération grasse, tumeur hépatique, dépôts et abcès metastatic de foie. De ces derniers la conclusion le plus généralement associée avec la pathologie discernable de foie était des ascities. Notre analyse suggère que le sonology de foie soit utile pour confirmer des cas médicalement suspectés de pathologie de foie et pour indiquer des formes négatives positives et fausses fausses de foie.

INTRODUCTION

One of the commonest problems of liver diseases on clinical examination arises from the ability to palpate the liver in a patient with suspected liver diseases. Generally, the mass turns out to be Riedel's lobe. Analysis of radioisotope and ultrasound scans show that many livers, which should be palpated, cannot be felt. It would seem that the ability to feel the liver is probably related to its

consistency and alteration in disease conditions. Structures, which commonly alter the liver shape, are the diaphragm, the kidney, the gall bladder and upper abdominal linings.

Individual component echoes of an organ lie as transverse streaks across the direction of interrogation. Electronic factors include any non-linear processing applied to the ultrasound signal. the important ones are listed appropriate compensation of receiver gain defines the fact that variations in transmission powder have no effect.

Another factor that helps in observing the liver is its texture. Finer textures of the liver are achieved by high frequencies, short pulse lengths and tight focusing of ultrasound beam. This factor varies with the depth so that the spot size of the final image is smallest (when resolution is best) in the focal zone of the transducer. Distortions of the sound beam are commonly produced by fibrous overlying tissue, (for-example, in cirrhosis), variation in normal tissue size and overlying tissue that ultrasound has to pass through.

It is therefore unquestionable that a liver ultrasound scan, which is non-invasive, non-ionizing, cost effective and time conserving,⁽¹³⁾ is the most sensitive screening tool for sorting out the organ involved in patients with abdominal symptoms.^(2,8,16) It can, by identifying the target organ, cut down the cost considerably by reducing superfluous investigations and ultimately length of hospital stay. Clinicians are thus encouraged to use ultrasound as the initial investigation of choice for patients with abdominal/suspected liver pathology.

In this study, we sought to find out how this modality has assisted in the diagnosis of these problems in our environment and the patterns of ultrasonic changes usually encountered in diagnosis of liver pathology.

MATERIALS AND METHODS

The ultrasound requests and results of all patients who had ultrasound of the abdomen in 2001 and 2002 were studied. To qualify for this study, the patients must have had full examination of the liver and other abdominal viscera. Patients referred for gynaecologic/obstetric scans were excluded as they frequently do not have detailed upper abdominal examination. All patients who must have also been referred on a clinical suspicion of an abdominal pathology were included.

RESULTS

Table 1 shows the analysis of 879 patients that underwent abdominal sonography during the period of study. This reveals the relative incidences of the organs involved.

Figure 1 illustrates the percentages of organ involvement in these patients.

Table 2 shows a comparison between ultrasonic findings and clinical indication

Of the total number of patients 287 (32.7%) with positive ultrasound findings for liver pathology, 46% (133 cases) were clinically suspected to have liver related pathologies (as indicated on their request forms) while 54% (154 cases) were not suspected clinically. 7.3% (43 cases) out of those clinically suspected to have pathology related to the liver were ultrasonically negative.

Table 3 is the analysis of specific entities showing their numbers and percentages. It is seen that hepatomegaly (38%) tops up the list followed by cirrhosis (21%). Analysis of their patterns of presentation, showed that ascities 43 cases (15%) was the most commonly associated finding with detectable liver pathologies.

Figure 2 further illustrates the number and percentages of these entities.

DISCUSSION

Ultrasound is considered the most cost effective primary investigation for liver pathologies and indeed right upper abdominal problems.^(2,8,16) This is partly because the liver readily lends itself to ultrasound imaging as it allows good transmission and reflection of sound waves and has no interposing gas shadows between it and the ultrasound probe. Also it is cheap, non-ionising, convenient and effective.⁽¹³⁾

The value of ultrasound is however 'user-operator' dependent.^(9, 17) In competent hands, it can give a specificity of 100% and a sensitivity of 70%.⁽¹⁾ In the diagnosis of hepatic metastatic deposits, it has been shown to have an accuracy ranging between 80%⁽¹⁶⁾ and 88%.⁽⁷⁾

Ultrasound using real time gray scale imaging can detect a broad spectrum of hepatic pathologies including neoplasms, abscesses, fatty degeneration, cirrhosis, cysts etc.^(8, 11) It is also useful in the pre and post operative assessment of liver transplant patients. With the advent of Doppler and colour Doppler it is comparable to angiography in it's ability to show tumor blood flow.⁽¹⁵⁾ In addition, it finds ready use in portal hypertension for visualisation of collateral circulation, measurement of the portal vein, splenic vein and post operative assessment of porto systemic shunts.^(8,10)

Ultrasound is also used in guiding interventional procedures e.g. abscess aspiration and liver biopsies where they have been proven to be less invasive, carrying a very low risk.⁽³⁾ It is also used to guide percutaneous treatment of hepatocellular carcinoma.⁽⁴⁾

One of the drawbacks of ultrasound is that though it is very sensitive in defining focal hepatic lesions,^(16, 17) diffuse disease e.g. fatty liver and

cirrhosis is not so well differentiated.⁽¹⁰⁾ Computed tomography in comparison gives better specificity. The attenuation value of any lesion e.g. fatty degeneration or hemochromatosis can be rapidly checked and a diagnosis made. With the use of spiral CT and intravenous enhancement, characteristic enhancement patterns of certain focal lesion e.g. focal nodular hyperplasia or haemangioma can be noted and a specific diagnosis made.⁽⁸⁾ Cysts and abscesses have characteristic appearances and cysts can be identified when as small as 5mm.⁽¹⁰⁾

The greater sensitivity and specificity of CT is also assisted by the fact that it has a greater capacity in the diagnosis of concurrent extrahepatic lesions.⁽¹²⁾

Due to it's greater cost, relative unavailability in developing countries and high dose of ionising radiation, CT is not recommended as a first line investigative tool but reserved for difficult equivocal cases or non response to therapy.^(12, 13, 16)

Another radiologic method that can be used in assessing the liver is radio-isotope scanning. It's use is mainly in detecting focal lesions. Masses smaller than 2cm are usually not resolved.^(8, 17) Superficial lesions are more easily resolved than deeper ones. Single Photon Emission computed Tomography (SPECT) solves this problem and improves the picking rate but not up to the level of CT. The sensitivity in detecting hepatic metastasis is put at 85% but its specificity is low.⁽⁸⁾

Magnetic Resonance Imaging (MRI) of the liver can also be done. It is most successful in characterising focal lesions.

Attributes include: Good morphologic demonstration and signs of adjacent spread. Demonstration of physicochemical composition and perfusion of hepatic lesions. Cellular

Table 1

Organs involved	Liver	Kidney	Spleen	Pancreas	Gall bladder	Total
No. of Patients	287	112	50	12	19	480
Percentage	60	23	10	3	4	100

Fig. 1
Relative Incidences of Organ Involvement

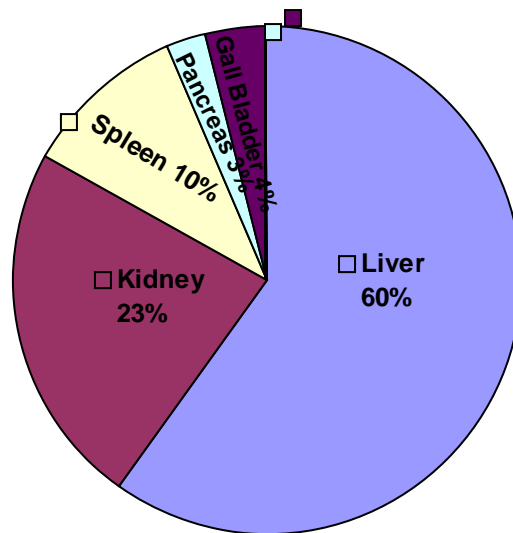


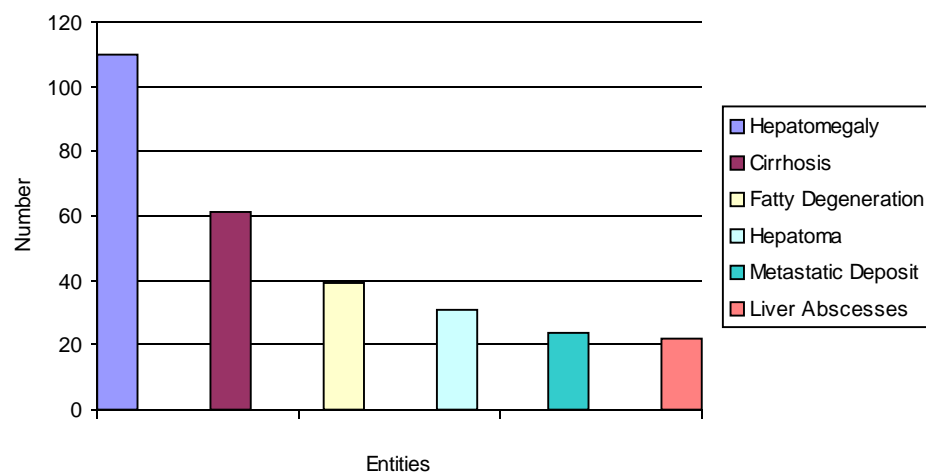
Table 2
Ultrasonic Findings Compared with Clinical Indication

Ultrasonic Findings	Clinical Liver Indication	Percentage	Total No.	
+ve (32.7%)	+ve	46	133	
	-ve	54	154	287
-ve (67.3%)	+ve	7.3	43	
	-ve	92.7	549	592

Table 3
ANAYSIS OF SPECIFIC ENTITIES

Ultrasound Detectable Pathology	Number	Percentage
Hepatomegaly	110	38
Cirrhosis	61	21
Fatty Degeneration	39	13.6
Hepatoma	31	11
Metastatic Deposit	24	8.4
Liver Abscesses	22	7.6

Fig. 2
Histogram of Number and Percentages of these Entities



References

1. Debongnie JC, Pauls C, Fievez M, Wibin E. Prospective evaluation of the diagnostic accuracy of Liver Ultrasonography. *Gut* 1981; (2): 130 5.
2. Mendelson RM; Kelsey PJ. Ultrasound and Liver Disease. *Australia Family Physician* 1995; (3): 360 - 3.
3. Antonucci F; Stuckmann G, Burger H.R. Otho R.C. Ultrasound Guided Incisional Biopsy in generalized and focal diseases of the Liver. *Ultraschall Med* 1986; (5) 203 8.
4. Nicolau C, Bianchi L, Vilana R. Gray Scale Ultrasound in Hepatic Cirrhosis and Chronic Hepatitis: Diagnosis, Screening and Intervention. *Semin Ultrasound CT, MR* 2002; (1): 3 - 18
5. Joseph AE, Dewbury KC, Mc Guire PG. Ultrasound in the Detection of Chronic Liver Disease (the "bright liver") *British Journal of Radiology* 1979; (615): 184 8.
6. Kamin PD, Bernadino ME, Green B. Ultrasound Manifestations of Hepatocellular Carcinoma. *Radiology* 1979; 131 (2): 459 61.
7. Cave-Bigley DJ and Lamb GH. The Value of Pre-operative Ultrasound of the Liver in Colonic and gastric Neoplasia.
8. Dick R, E Rhys-Davis, Whitehouse WR, Lees WR, Robinson PJA. Textbook of Radiology and Imaging Edited by Sutton D. 1010, 1016; 996 8; 1019.
9. Connor SEJ, Banerjee AK. General Practitioner requests for Upper Abdominal Ultrasound: their effect on clinical outcome. *The British Journal of Radiology*, 71 1998; 1021 1025.
10. Hagen Anset S. Hepatobiliary Disease: Focus on Hepatitis, cirrhosis, hepatitis, Cirrhosis, Hepatocellular Carcinoma and Liver Transplantation. Online CME Courses.
11. Njoya O, Ndam EC, Ngoue V, Sende CN. Amobic Liver Abscesses in Yaounde Sante 1999; (2): 119 22.
12. Stoopan M, Kimura K. Amebiasis. The Technology of the 90's. I. Ultrasound, computerised Tomography and Magnetic Resonance have they helped improve the diagnosis of hepatic abscess? *Rev. Gastroenterol Mex* 1989; 54 (3): 107 75.
13. Palmer P; Reeder M. The Radiology of Tropical Diseases. 41.
14. Murfitt J. A Concise Textbook of Clinical Imaging Edited by Sutton D. and Young WJR. 486 and 487.
15. Taylor K.J.W, Ramos I., Morse S. S. et al. Focal liver masses: differential diagnosis with pulsed Doppler ultrasound. *Radiology*, 1987; 163, 830. Cited by Dick R. et al.
16. Schreve RH, Terpstra OT, Ausema L, Lameris JS, Van Seijen A J, Jeekel J. Detection of Liver Metastasis. A prospective study comparing liver enzymes, scintigraphy, ultrasonography and computed tomography. *British Journal of Surgery*. 1984; 71: 947 949.
17. Tempero MA, Williams CA Anderson JC. The value of Hepatic Ultrasound and Biochemical Liver tests in Screening of Liver Metastasis. *Journal of Clinical Oncology*, 1986; 4(7): 1074 1078.