

TAKAYASU ARTERITIS IN JOS NIGERIA. A CASE REPORT.

By

Dr. B. N. Okeahialam FWACP, Dr. N.C. Obeka M.B.B.S.*, Dr. J. E. Ekedigwe FWACS**,
Dr. A. Z. Sule FWACS***, Dr. M. U. Sani FWACP**

**Department of Medicine, Jos University Teaching Hospital, Jos Nigeria,*

***Department of Radiology, Jos University Teaching Hospital, Jos Nigeria,*

****Department of Surgery, Jos University Teaching Hospital, Jos Nigeria.*

Correspondence to BNO E mail okeahbas@unijos.edu.ng

*MUS: Currently at- Department of Medicine, Aminu Kano Teaching Hospital,
Kano, Nigeria.*

INTRODUCTION

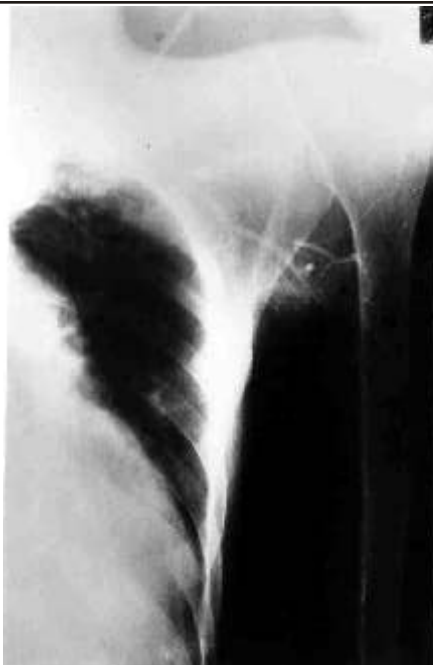
Takayasu arteritis (TA) is a chronic vasculitis of unknown aetiology involving the aorta and its major branches. It could also involve the coronary and pulmonary arteries. It was first noted in 1908 by a Japanese ophthalmologist, Mikijo Takayasu, who described the case of a 21 year old woman whose optic fundi exhibited peculiar anastomosis¹. The disease has a worldwide distribution, but it is more common in South East Asia. It affects mainly young women, who account for about 90% of all cases in a series from Japan². An international survey by Nuneuro et al showed that the female to male ratio decreases as one moves from east to west³. On the African scene, few cases have been reported^{4, 5}. The cases that have been reported from South-West Nigeria were all females⁶. We hereby report a case of TA in an adult Nigerian from the North. This to the best of our knowledge is the first case reported in a Nigerian male in literature.

CASE REPORT

V.G. was a 32 year old man was admitted with a diagnosis of dilated cardiomyopathy in congestive cardiac failure. He was referred to the Cardiology unit when his heart failure was adjudged refractory by the managing unit. Following evaluation which included multiple blood cultures that yielded

positive result, aortic regurgitation and infective endocarditis (IE) were discovered. Absent left upper limb pulses and non-recordable blood pressures were noted and thought to be related to the IE. He did not show any sign of gangrene in the affected limb. He was appropriately treated, fared better and was later discharged.

He was re-admitted in heart failure soon after discharge. Further questioning revealed history of left upper limb claudication and hypertension early in life. Clinical examination revealed absent left radial and brachial pulses, collapsing right radial pulse, an aortic incompetence murmur (grade 3/6) and biventricular failure. His erythrocyte sedimentation rate was 51mm/hr (Westergren). Mantoux test, rheumatoid factor, HIV screening and Veneral Disease Research laboratory (VDRL) tests were all negative. Echocardiography revealed marked left ventricular dilatation that was hypokinetic, a dilated aortic root and moderate aortic incompetence. Selective aortography showed tubular left subclavian artery with stenosis just proximal to the axilla (fig. 1). A later film showed extensive collaterals (fig. 2)



Selective aortography showed tubular left subclavian artery with extensive collaterals

DISCUSSION

It is now established that TA is far from being exclusively the disease of Asian women⁵. However previous Nigerian reports suggest that the disease is very rare in our environment. This rarity, we suspect, may be in part due to underdiagnosis and under-reporting. Although a specific cause has not been found⁷, the bulk of evidence favours an auto-immune aetiology. An association between the disease and certain HLA subtypes has been reported^{8, 9, 10}. In the early stage of the disease, there is active inflammation affecting the intima, media and adventitia of the aorta and its branches. The disease progresses at variable rates to a later sclerotic stage. The clinical manifestations of TA are usually localized pain and symptomatology of regional ischaemia from stenosis and thrombosis.

Involvement of the ascending aorta may cause aortic regurgitation. More acute progression causes aneurysms or rarely rupture of the involved arteries.¹¹ Death usually results from complications of renovascular hypertension. Inflammatory markers are usually raised during the acute systemic phase. Diagnosis is confirmed by imaging assessment with arteriography, computed tomography, magnetic resonance and digital subtraction angiography. Early diagnosis with the aid of these modern facilities and thereby early treatment have made a better prognosis possible.¹²

Our patient had features consistent with the American College of Rheumatology 1990 criteria for the classification of TA¹³. He presented at < 40 years, had claudication of an extremity, absent brachial arterial pulse and arteriographic evidence of narrowing of the left subclavian artery. Unfortunately he, like all reported cases in Nigeria was diagnosed in the late sclerotic phase of the disease. He died suddenly at home apparently from complications of his refractory congestive cardiac failure.

It is said that vasculitis is a difficult diagnosis to establish with diagnosis being made only at autopsy¹⁴. Biopsy, which should confirm it, is difficult here because of location of the affected vessels. Arteriographic evidence of a tubular vessel that narrows abruptly in a clinical setting where atherosclerosis is unlikely is therefore considered diagnostic¹⁴. The clinical manifestations and the angiographic evidence of this case are typical.

In the absence of modern diagnostic facilities for early diagnosis in most Nigerian centers, a high index of suspicion becomes necessary. Early non-specific presentation of the disease often results in delayed diagnosis. TA may not

be as uncommon with us as previously believed. It is hoped that an increased awareness of this condition will generate interest in early diagnosis and therefore make treatment possible.

In conclusion, TA should be considered among diagnostic possibilities in Nigerian patients who present with unexplained systemic inflammation suggested by a high erythrocyte sedimentation rate. Where possible, angiography should be done to confirm diagnosis.

Acknowledgement: We wish to thank Dr. A.I. Zoakah, the Director of Clinical Services and Training of the hospital for waiving the investigation (angiography) bill of the patient.

REFERENCES

1. Numano F, Kakuta T. Takayasu arteritis II. Five doctors in the history of Takayasu arteritis. *Int J. Cardiol* 1996; 54(Suppl): S1-S10.
2. Koide K. Takayasu arteritis in Japan. *Heart Vessels* 1992; 7 (Suppl): 48-54.
3. Numano F. Differences in clinical presentation and outcome in different countries for Takayasu arteritis. *Curr. Opin Rheumatol* 1997; 9:12-15.
4. Ladipo F. Roentgen diagnosis of a case of Takayasu's arteriopathy. *Nig Med J.* 1976; 6:92-3.
5. Bouramoue C, Assounga AGH. La maladie de Takayasu: A propos de 4 cas observes a l'Hospital ge'ne'ral de Brazzaville (Congo) *Trop. Card* 1986; 12(46):45-50.
6. Ogunbiyi OA., Falase AO. Aortic arch syndrome Takayasu's arteritis in Nigeria. *Afr.J. Med. Med. Sci.* 1989; 18:211-214.
7. Shelhamer JH, Volkman DJ, Parillo JE et al: Takayasu's arteritis and its therapy *Ann. Inten Md.* 1985; 103:121.
8. Kimura A, Kitamura H. Date Y, Nunano F. Takayasu arteritis III: Comprehensive analysis of HLA gene in Takayasu arteritis in Japan. *Int. J. Cardiol* 1998; 54(Suppl): 565-73.
9. Girona E, Yamamoo Furusho JK., Cutino T, et al: HLA-DR6 (possibly DRB1*1301) is associated with susceptibility to Takayasu arteritis in Mexicans. *Heart Vessels.* 1996;1(6):277-80.
10. Mehra NK Rayalingam R, Soyar S, Jain S. Sharma BK, Direct role of HLA B5 in influencing susceptibility to Takayasu aorto arteritis *Int J. Cardiol.* 1996;54(Suppl):571-79.
11. Numano F. Takayasu arteritis beyond pulselessess. *Intern Med* 1999; 38:226-32.
12. Numano F, Okawara M, Inomata H, Kobayashi Y. Takayasu's arteritis. *Lancet* 2000;356:1023-25.
13. Arend WP, Michel BA, Bloch DA, Hunder GG, et al. The American College of Rheumatology 1990 Criteria for the classification of Takayasu arteritis. *Arthritis Rheum.* 1990;33(8): 1129-34.
14. Parrillo JE, Fauci AS. Necrotising vasculitis, Coronary angiitis and the Cardiologist. *American Heart J.* 1980 99(5) 547-554.